

6-1963

Observations On The Gastrointestinal Administration Of Bovine Splenic, Renal And Muscle Homogenates On Hematopoiesis In Man

Raymond W. Monto

James A. Barron

John W. Rebuck

Follow this and additional works at: <https://scholarlycommons.henryford.com/hfhmedjournal>

 Part of the [Life Sciences Commons](#), [Medical Specialties Commons](#), and the [Public Health Commons](#)

Recommended Citation

Monto, Raymond W.; Barron, James A.; and Rebuck, John W. (1963) "Observations On The Gastrointestinal Administration Of Bovine Splenic, Renal And Muscle Homogenates On Hematopoiesis In Man," *Henry Ford Hospital Medical Bulletin* : Vol. 11 : No. 2 , 147-155.

Available at: <https://scholarlycommons.henryford.com/hfhmedjournal/vol11/iss2/4>

This Article is brought to you for free and open access by Henry Ford Health System Scholarly Commons. It has been accepted for inclusion in Henry Ford Hospital Medical Journal by an authorized editor of Henry Ford Health System Scholarly Commons. For more information, please contact acabr4@hfhs.org.

OBSERVATIONS ON THE GASTROINTESTINAL ADMINISTRATION OF BOVINE SPLENIC, RENAL AND MUSCLE HOMOGENATES ON HEMATOPOIESIS IN MAN

A PRELIMINARY REPORT

RAYMOND W. MONTO, M.D.*; JAMES A. BARRON, M.D.**

AND JOHN W. REBUCK, M.D., PH.D.***

THE SPLEEN HAS been an organ of mystery and controversy since the beginning of medicine.¹ The influence of the spleen upon maturation and release of the bone marrow elements continues to be the subject of intensive investigation. The concept of hypersplenism as well as the role of the spleen and auto-immune disease is now well documented. Instances of "hyposplenism" have not been recognized. Hence, there still remains the question of a stimulatory, as well as an inhibitory, influence of the spleen in hematopoietic and auto-immune syndromes.

In 1956 Jacobson observed that shielding the spleen or the intravenous injection of splenic homogenates offered protection against the exposure of x-ray radiation in animals.² Berliner, in 1961, described a patient with hemorrhagic thrombocytopenia successfully treated with raw spleen administered orally in the amount of 100 gm. daily.³ Crosby, in 1962, found that after splenectomy rats developed lasting thrombocytosis and leukocytosis of moderate degrees. When these animals were placed on a diet of raw spleen, the white cell and platelet counts were promptly suppressed and remained so until the diet was returned to regular laboratory chow. Control animals with spleens intact developed leukopenia and thrombocytopenia on a diet of raw spleen.⁴

A number of organs, including glandular tissues, have been studied in relation to hematopoiesis.⁵ The kidney is considered an important factor in the production of erythropoietin, but a product of this organ or other sources is not available for

Investigation supported in part by Public Health Service Grant No. CA 04915-04.

*Division of Hematology.

**Department of Surgery.

***Department of Laboratories.

human application.⁶ This report constitutes preliminary observations upon a group of patients with a variety of hematologic disorders who received fresh bovine spleen, kidney and muscle homogenate via an intragastric tube.

METHODS

Fresh, whole, bovine spleen was obtained the morning of the kill from a slaughter house and transported on ice. The organs averaged 700 gm. in weight. The spleens were trimmed of fat, large vessels and a major portion of the peritoneal covering. The average trimmed spleen weighed approximately 500 to 600 gm. Figure 1 represents an imprint of fresh bovine spleen. The organs were processed twice through a conventional hamburger-type grinder. The ground spleen was then passed through a food mill which produced a homogenate, consisting of particulate matter with only a few remaining intact cells. During the process of homogenization, the material was cooled and diluted with 5 per cent glucose in water. Figure 2 demonstrates the findings of a stained smear of the final product showing particle size and an occasional intact nucleus.

The final homogenate was bottled in liter glass flasks which contained approximately 500 gm. of fresh spleen in 500 cc. of 5 per cent glucose in water. The final product was kept under refrigeration and, in most instances, administered within 48 hours. On occasion, frozen material was employed when the fresh product was not available.

Biochemical analysis of the splenic homogenate showed it to contain about 5 per cent protein and 700 mg. per cent total lipid. The electrophoresis of the homogenate demonstrated the majority of the soluble protein to appear in the betaglobulin range.

Kidney and lean muscle were obtained 24 hr. after the kill and prepared by the same method and in similar concentration.

A fine polyethylene tube was passed through the patient's nose and the tip placed in the stomach. This tubing was then connected to the Barron Food Pump and operated at speed #3 or #4. Approximately 1000 gm. of fresh bovine spleen, kidney and muscle were

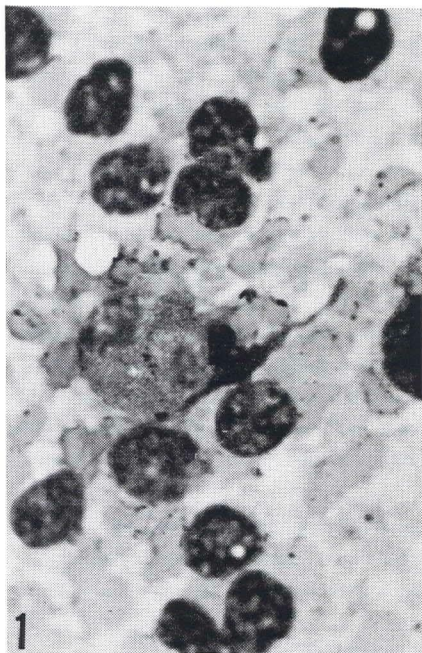


Figure 1

Imprints of fresh bovine spleen X1100.

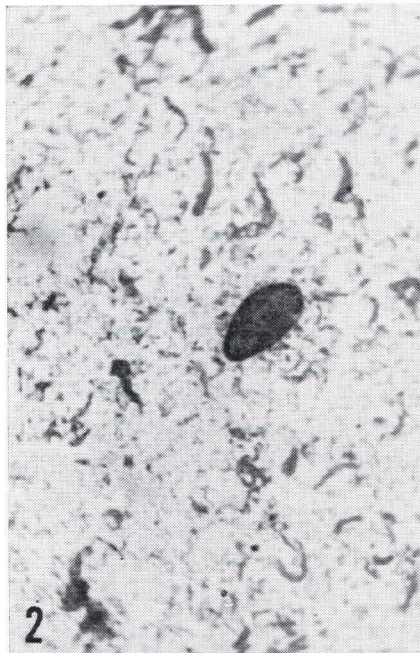


Figure 2

Final splenic homogenate X1100.

OBSERVATIONS ON HEMATOPOIESIS

administered daily during a period of 10-12 hr. Gastrointestinal intolerance was rare and complications consisted of an occasional loose bowel movement or tendency towards fecal impaction. The patients were permitted to eat regular meals if they desired, but, in most subjects, the appetite was inhibited.

Prior to the administration of the homogenate, appropriate blood counts, bone marrow smears and sections were obtained which were repeated at intervals. Serum urea nitrogen (SUN) and uric acid levels were determined every two days.

RESULTS

A total of 11 patients received 17 feedings. Fourteen were splenic homogenates, two were kidney and one beef muscle.

CASE 1 — Diagnosis: Factor IX deficiency (plasma thromboplastin component). White, male, aged 28 yrs., wgt., 73 kilo.

The patient did not demonstrate signs or symptoms of active disease and served as a "control". A thousand gm. of the spleen homogenate were administered daily for ten days. During this time the red blood cell increased from 4.2 mil. to 4.69 mil. and the hemoglobin from 14.3 gm. to 15 gm. per cent. The white blood cell count was unchanged. The reticulocytes increased from 1.5 per cent to 3.4 per cent. The hematocrit before onset of therapy was 43 per cent and after 10 days 45 per cent. On the 5th day of therapy the platelet count increased to a level of 387,000 per cu. mm. from an original determination of 232,000. The thrombocytosis was transient and returned to 277,000 by the 10th day. SUN rose from 14 mg. per cent to 20 mg. per cent. The original serum uric acid blood level was 3.4 mg. per cent and on the 10th day rose to 10.2 mg. per cent. While the coagulation times did not improve significantly during the treatment, the plasma clotting time decreased from 416 seconds to 355 seconds; the prothrombin time from 19 seconds to 17 seconds; and the prothrombin consumption from 16.3 seconds to 18 seconds. The 2 stage prothrombin determination before therapy was 129 units and after therapy 210 units. At a later date this patient received 1000 gm. of beef homogenate daily for 8 days without alteration of the peripheral blood count, uric acid, or coagulation studies.

CASE 2 — Diagnosis: Multiple sclerosis, advanced, with paraplegia, severe chronic cystitis and pyelonephritis, multiple deep decubitus ulcers, associated with malnutrition, "control". White, male, aged 34 yrs., wgt., 43 kilo.

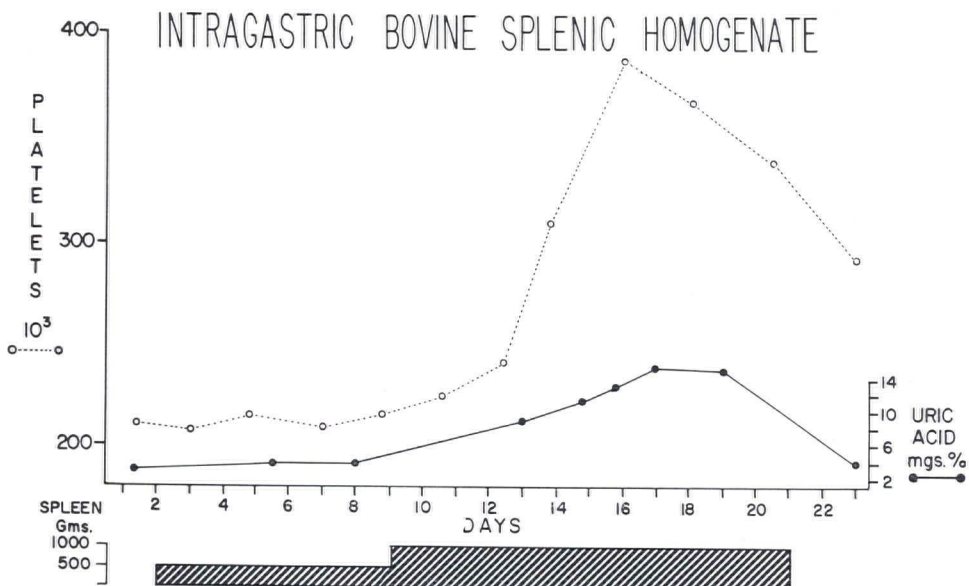


Chart I

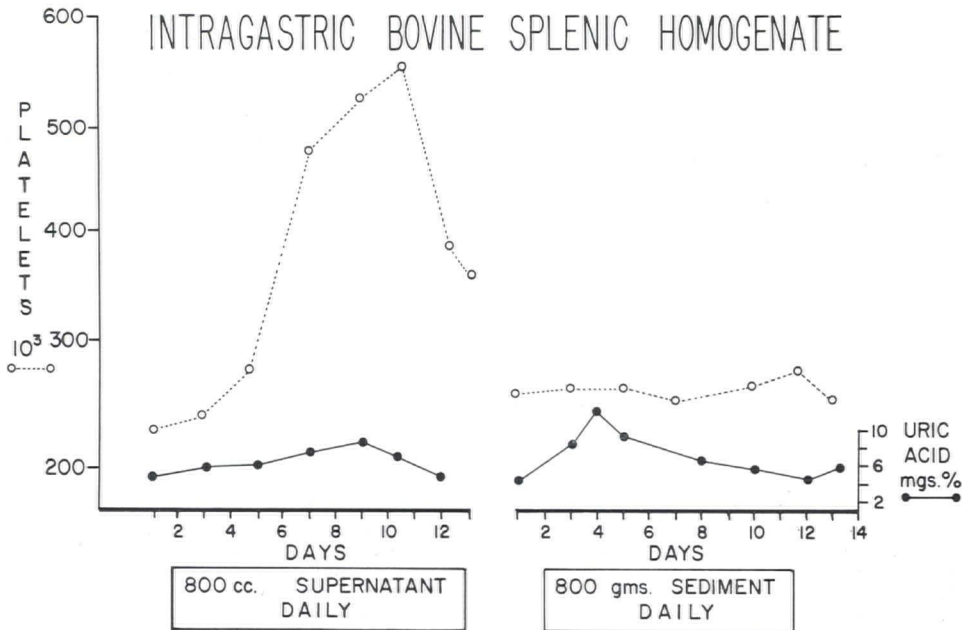


Chart II

Before administration of splenic homogenate the patient had been on a homogenized regular hospital diet fed intragastrically. The initial course of therapy consisted of 500 gm. of splenic homogenate without apparent hematologic response or increase in SUN or uric acid (Chart I). The feeding was increased to 1000 gm. per day and on the 7th day the platelet count rose from an original level of 212,000 per cu. mm. to 377,000. The uric acid level at onset was 6.4 mg. per cent. There were no significant alterations of the white or red cell count. The serum electrophoresis was not altered during this course of therapy. While receiving 1000 gm. of splenic homogenate a day, the uric acid level reached 12.9 mg. per cent by the 10th day.

Later this same individual was administered 800 cc. of the splenic supernatant obtained by high-speed centrifugation of the total homogenate (Chart II). The platelet count rose from an original level of 240,000 per cu. mm. to 550,000 on the 11th day of therapy. Only minimal increases in serum uric acid levels were encountered. Subsequently, the thawed frozen sediment of the splenic homogenate obtained from the previous centrifugation was given to the patient in the amount of 800 gm. daily (Chart II). There was noted no significant alteration of the blood platelet count, and the maximum uric acid level reached was 10 mg. per cent on the 4th day of therapy. After an interval of 7 days this individual received 1000 gm. of homogenized bovine kidney over a 14 day period. Aside from minor increase in reticulocyte count from 2.4 per cent to 4.1 per cent and an elevation of uric acid from 3.8 mg. per cent to 5.8 mg. per cent, there were no significant alterations of the red and white cell count or blood platelets.

CASE 3 — Diagnosis: Hypoplastic anemia, severe. White female, aged 80 yrs., wgt., 51 kilo.

The patient was severely pancytopenic with generalized bleeding phenomena related to extreme thrombocytopenia. The original course of therapy consisted of 500 gm. of splenic homogenate daily for nine days. The peripheral blood elements did not change significantly. The blood uric acid level rose from initial 2 mg. per cent to 5.3 mg. per cent. A second course of therapy consisted of 1000 gm. of splenic homogenate daily. Hemoglobin and red cell response could not be ascertained for reason of intermittent bleeding and transfusion need. A white blood cell count rose from 2,400 to 5,300 per cu mm. No significant change occurred in the circulating blood platelets. The blood uric acid level reached 6.8 mg. per cent on the 8th day. The most striking effect was seen in this patient's bone marrow section before therapy (Figure 3), and after completion of therapy (Figure 4).

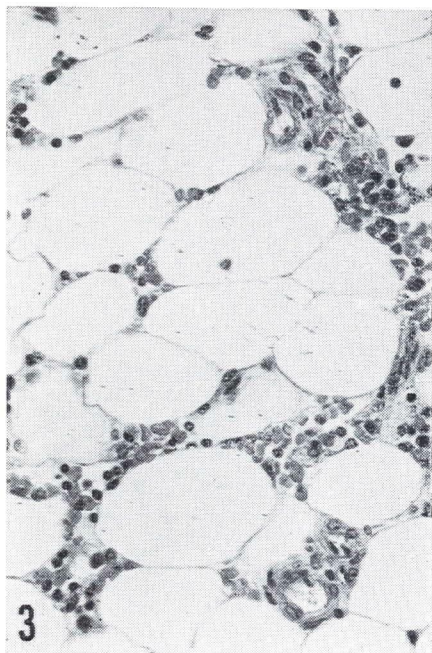


Figure 3

Case 3 — Aspirate section of marrow before therapy showing aplasia X300.

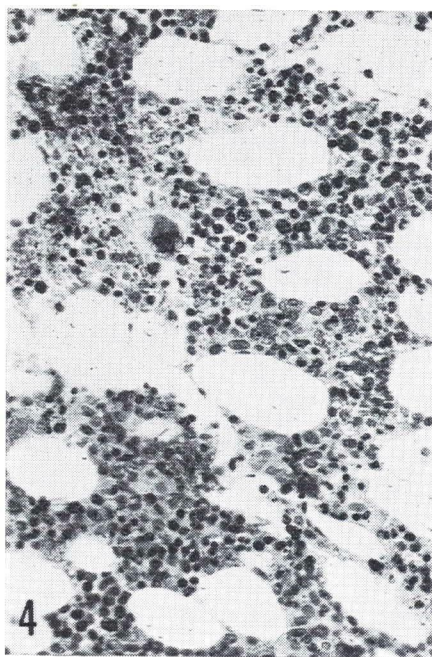


Figure 4

Case 3 — Aspirate section of marrow after therapy. Note return to normal cellularity except for megakaryocytes X300.

CASE 4 — Diagnosis: Congenital familial erythroblastopenia (congenital hypoplastic anemia) previously splenectomized. White, male, aged 22 yrs., wgt., 70 kilo.

This patient was complicated with severe cirrhosis, myocarditis and polyglandular insufficiency. The initial red blood cell count was 1.21 mil., hemoglobin 6.2 gm. per cent and white blood cell count 7,900 per cu. mm. Reticulocyte count was 1 per cent and platelet count 380,000 per cu. mm. and the hematocrit was 18 per cent. The bone marrow differential showed but 5.8 per cent erythroblasts (Figure 5). The initial SUN was 16 mg. per cent and the uric acid 2.6 mg. per cent. On the 4th day of therapy with bovine splenic homogenate the platelet count was elevated to 995,000. The thrombocytosis was sustained throughout the course of therapy and gradually fell to pretreatment level on completion of feeding. The reticulocytes increased to 5.7 per cent on the 10th day with an increase in red cell count to 1.67 mil. and hemoglobin to 7 gm. After completing the course of feeding, the progress bone marrow was performed and erythroblasts were now 18 per cent and the marrow seemed to have normal cellularity (Figure 6).

This patient was subsequently treated with 1000 gm. daily of homogenized kidney for 13 days without significant change in the hematologic values.

CASE 5 — Diagnosis: Acute auto-immune thrombocytopenic purpura in steroid relapse. White, male, aged 10 yrs., wgt., 27 kilo.

This individual did not respond to 500 gm. of splenic homogenate in a 7 day period, following which 1000 gm. daily was administered for six successive days. The original platelet count was 4,000 per cu. mm. This rose to 18,000 on the 9th day of therapy. A mild increase in the blood hemoglobin from 10.9 gm. per cent to 12 gm. per cent was noted. The white cell count increased from 4,300 to 10,400 on the 8th day of treatment. The reticulocyte count increased from 0.9 per cent to 3.3 per cent in 10 days associated with marked shift to the left in the white cell differential. While receiving 1000 gm. of homogenate daily, the uric acid levels reached 8.2 mg. per cent from an original level of 3.2 mg. per cent.

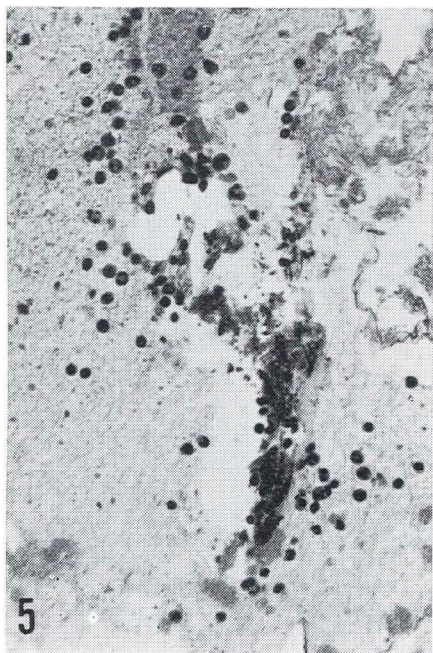


Figure 5

Case 4 — Aspirate section of marrow before therapy. Note bony spicule, fat cells and a few hematopoietic cells X300.

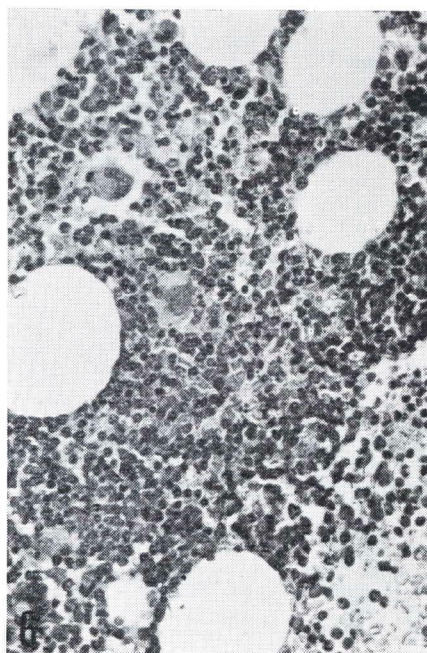


Figure 6

Case 4 — Aspirate section of marrow after therapy. Note hypercellularity of marrow with increase in normoblasts X300.

While the original bone marrow showed an adequate number of megakaryocytes (Figure 7), they were notably increased in the marrow following completion of the feeding (Figure 8). There was no significant alteration of the serum electrophoresis or total protein.

CASE 6 — Diagnosis: Intermittent acute auto-immune thrombocytopenic purpura, previously splenectomized White, female, aged 55 yrs., wgt., 51 kilo.

This individual was markedly thrombocytopenic with levels from 5 to 10,000 per cu. mm. for a two month period. She had failed to respond to adrenal corticosteroids which were discontinued. The patient received 1000 gm. of splenic homogenate for a 13 day period. On the 5th day of therapy the platelets had increased to 33,000. Improvement continued and a normal platelet count of 232,000 was encountered on the 14th day of therapy. She has maintained this level. Uric acid levels reached a maximum of 9.1 mg. per cent on the 7th day of therapy, and the SUN remained within normal limits. There were no significant alterations of the hemoglobin or white blood cell count. The original bone marrow examination revealed but few megakaryocytes in a mildly hypoplastic bone marrow. Following therapy there was an apparent increase in the number of megakaryocytes.

CASE 7 — Diagnosis: Myeloid metaplasia, agnogenic. White male, aged 75 yrs., wgh. 54 kilo.

Hemoglobin at onset of feeding with splenic homogenate was 10.5 gm. per cent and platelet count 32,000 per cu. mm. The patient was given intragastric splenic homogenate 1000 gm. daily for ten days. On the 10th day the hemoglobin was 12.4 gm. per cent and platelet count 95,000. The white cell count at onset of treatment was 77,000; on the 9th day it had fallen to 48,700 and in 15 days to 20,000. There was continued improvement in the platelet count to 102,500 on the 6th day of treatment by feeding.

CASE 8 — Diagnosis: Hodgkin's disease with severe toxicity, pancytopenia and bone marrow hypoplasia. White, male, aged 60 yrs., wgt., 70 kilo.

Patient received 1000 gm. of splenic homogenate for a 10 day period. Before therapy and for many months the platelet count had ranged from 30 to 40,000 per cu. mm. On the 4th day of intragastric administration of bovine splenic homogenate the platelet count

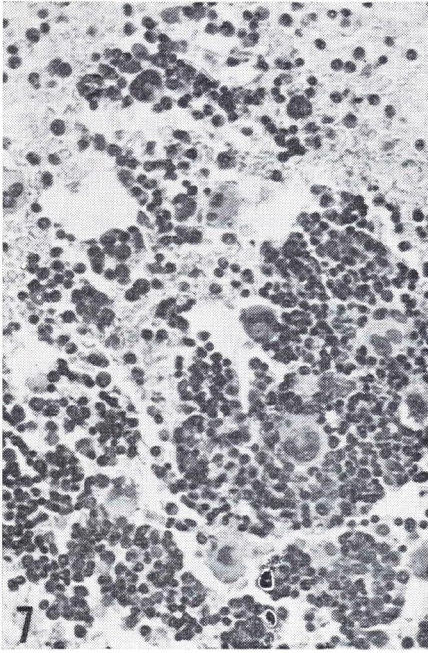


Figure 7

Case 5 — Aspirate section of marrow before therapy. Note full cellularity and numerous megakaryocytes X300.

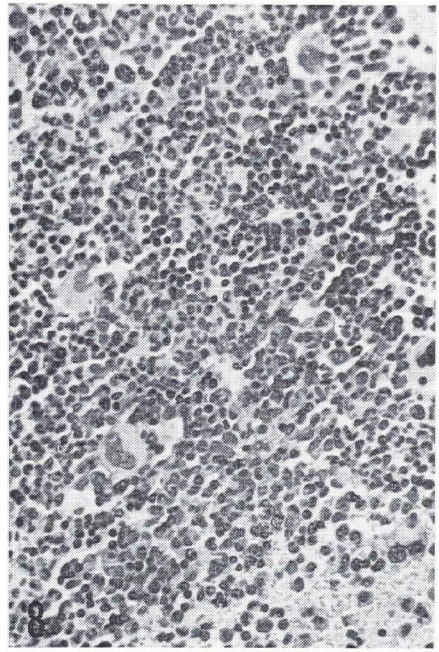


Figure 8

Case 5 — Aspirate section of marrow after therapy. Note marked hyperplasia X300.

was 155,000. Nitrogen mustard, 0.2 mg. per kilo, was given on two successive days. No gastrointestinal toxicity to the mustard occurred, and an excellent clinical response to mustard was encountered within four days. The platelet count continued to improve, reached a maximum of 175,000 during hospitalization and was maintained at a normal range of 200,000 for a period of months. During therapy the uric acid level of 11.7 mg. was encountered on the 9th day of therapy. The SUN advanced from a level of 12 mg. per cent before therapy to 29 mg. per cent on the 9th day. Following therapy these chemical values returned to normal limits.

CASE 9 — Diagnosis: Lymphosarcoma, terminal. White, female, aged 15 yrs., wgt., 31 kilo.

Received 600 gm. of splenic homogenate daily for 3 days. On the 3rd day of therapy the SUN rose to 94 mg. per cent from initial level of 24 mg. per cent and the uric acid from 3.6 mg. to 10.7 mg. per cent. These findings were associated with clinical signs and symptoms of uremia, and for this reason the findings were discontinued. Within 48 hours there was marked clinical improvement in her renal status and the SUN and uric acid returned to near normal levels. There were no significant changes in the peripheral blood counts.

CASE 10 — Diagnosis: Lymphosarcoma, asymptomatic. White, female, aged 52 yrs., wgt., 50 kilo.

This patient received 1000 gm. of splenic homogenate for ten days without significant alteration of the red cell count or the hemoglobin. The white blood cell count was 10,700 per cu. mm. at onset and on the last day of treatment was reported as 14,500. The blood platelets before therapy were 432,000 per cu. mm., rose to 600,000 on the 5th day of therapy and reached a peak of 647,000 on the 9th day of therapy. After discontinuance of the intragastric feedings the blood platelets were reduced to their pretreatment level.

CASE 11 — Diagnosis: Nutritional macrocytic anemia. White, female, aged 15 mo., wgt., 7 kilo.

The patient received only two administrations of intragastric bovine splenic homogenate in the amounts of 12 and 25 gm., respectively. For reasons of the serious clinical state of the patient, routine therapy was then instituted.

DISCUSSION

Numerous investigators have tested various fractions of both animal and human spleens in relation to hematopoiesis and protection against radiation with varying degrees of success.⁷⁻¹¹ The results of these experiences were not convincing and most often were controversial. Both an inhibitory and a stimulatory effect upon the bone marrow has been claimed. Failure in response to splenic material in some instances may be related to the mode of administration, the type of homogenate or the amount of the organ given.

The spleen is an organ with an exceedingly high nucleoprotein content. The cellular constituents are composed largely of the nuclear material desoxyribonucleic acid (DNA) and a smaller amount of ribonucleic acid (RNA), fractions of which some are soluble and insoluble. Speculation as to the mode of action of splenic homogenate administered gastrointestinally raises two possibilities. The material may contain a "hormonal-like substance" capable of being absorbed by the gastrointestinal tract. A second, and more plausible, explanation would be the absorption of degraded products of nucleoprotein in excess to enhance marrow function. Pisciotta¹² found that during bone marrow recovery from drug induced bone marrow toxicity, compensatory increases in DNA and RNA were capable of overcoming the depressant action of the drug *in vivo*.

Thrombocytosis with evidence of increased megakaryocytopoiesis was the most commonly encountered hematologic response in those patients receiving bovine splenic homogenate in this series. Case 3 and case 4 gave suggestive evidence of stimulation of erythrocytic and granulocytic cell lines of the bone marrows. Case 8 was of interest in view of apparent successful treatment with nitrogen mustard in the presence of severe pancytopenia and marrow hypoplasia. In case 7 reduction of the total leukocyte count from 77,000 to 20,000 per cu. mm. during the course of therapy was most noteworthy.

This data must be interpreted in the light of the natural courses of these disease states, together with pre- and current adjunctive therapy when indicated in the case abstracts.

Studies are currently underway as to the efficacy of stored frozen homogenate and supernatant fluid of the homogenate in both patients and laboratory animals.

CONCLUSIONS

1. Bovine splenic, renal and beef muscle homogenate have been administered to patients with various hematological disorders gastrointestinally by intragastric tube in the amounts of 1000 gm. daily, for periods of 7-14 days. This type of feeding is well tolerated.

2. Patients receiving bovine splenic homogenates regularly demonstrate thrombocytosis and increased megakaryocytopoiesis to varying degrees. In some patients there appears to be erythroid as well as myeloid bone marrow stimulation.

OBSERVATIONS ON HEMATOPOIESIS

3. In one patient it was possible to administer nitrogen mustard successfully in spite of a moderate pancytopenia and bone marrow hypoplasia.
4. Bovine renal and muscle homogenates in three patients produced no significant hematologic alteration.
5. The data presented indicates the need for further evaluation.

REFERENCES

1. Blaustein, A. U.: *The Spleen*, New York, The Blakiston Div., McGraw-Hill, 1963.
2. Jacobson, L. O.: Hematopoietic responses to irradiation injury, *Ann. Rev. Med.* 7:345, 1956.
3. Berliner, G. B.: A case of hemorrhagic thrombocythemia successfully treated with raw spleen, *Probl. Gemat. (Eng.)* 6:189, 1961.
4. Crosby, W. H. and Ruiz, F.: Evidence of a myeloinhibitory factor in the spleen, Fifth Annual Meeting, American Society of Hematology, Nov. 26, 27, Columbus, Ohio, 1962.
5. Erslev, A. J.: Erythropoietin in vitro. In, *Conference on Erythropoietin and Regulation of Erythropoiesis, 1962.* ed. by L. O. Jacobson and M. Doyle. New York, Grune and Stratton, 1962, p. 275.
6. Jacobson, L. O., Goldwasser, E., Fried, W., and Plzak, L.: Role of kidney in erythropoiesis, *Nature* 179:633, 1957.
7. Albert, H. H., von: Inhibiting effects of splenic extracts from patients with hypersplenism on bone marrow culture, *Klin. Wschr.* 40:211, 1962.
8. Miya, F., Thorpe, B. D., and Marcus, S.: Failure of cell-free spleen extracts to protect irradiated animals, *Proc. Soc. Exp. Biol. Med.* 101:433, 1959.
9. Ellinger, F.: Protection of guinea pigs against radiation death by cell-free mouse spleen extract, *Science* 126:1179, 1957.
10. Watson, G. F.: Treatment of cancer cases with spleen extract given intravenously and a concentrated extract given subcutaneously, *Acta Un. Int. Cancr.* 16:1220, 1960.
11. Schleicher, E. M.: Effect of orally administered desiccated beef spleen and abdominal lymph nodes on megakaryocytogenesis and thrombocytes, *Acta. Hemat.* 5:143, 1951.
12. Pisciotta, A. V., Keller, C., Callaghan, J. L., and Kaldahl, J.: Patterns of recovery from drug-induced bone marrow damage, Fifth Annual Meeting, American Society of Hematology, Nov. 26, 27, Columbus, Ohio, 1962.

